



PATIENT

Paisley Roshuk

SPECIES

Canine

BREED

Boxer

SEX

Female Spayed

AGE

4years

WEIGHT

49.2lbs

INTERPRETED BY

Maggie Machen Lamy,
DVM, DACVIM
(Cardiology)

IMAGING PERFORMED BY

C. Belan, DVM

HOSPITAL NAME

Fish Creek Animal
Clinic

REFERRING VET

Dr. Van Sluys

INVOICE

29639

DATE

3/16/23

PRESENTING CLINICAL SIGNS

History: Recheck echo. Assess prior to surgery for mast cell tumor planned for Monday.
-Pertinent previous echo findings (10/2021 MML): Trivial MR, mild LAE, normal LV, mild aortic thickening, mild AS with trace AI. AV max: 2.7, LV: 3.9/2.4, LA: 2.8.

ECHOCARDIOGRAM FINDINGS

2D, m-mode, color flow and doppler imaging is available. Normal mitral valve leaflets with no prolapse into the left atrial lumen. No mitral regurgitation with mild left atrial dilation. Normal LV diameter with adequate myocardial function. Normal LV wall dimensions with no obvious hypertrophy. The tricuspid valve appears normal with no tricuspid regurgitation. Normal right atrial and ventricular diameter and morphology indicating no overt evidence of pulmonary arterial hypertension. The pulmonic valve appears normal in morphology and mobility. Normal pulmonic outflow velocities with laminar flow. Mild thickening of the aortic valve; mildly increased LVOT velocity consistent with stenosis. Trace aortic insufficiency. No pericardial or pleural effusion noted. No obvious cardiac masses.

CARDIAC CHART

CANINE CARDIAC PARAMETERS	MR VMAX (m/s)	TR VMAX (m/s)	LA/AO (Boon method)	LA/AO (Heart Base; Swe)	FS (%)	EF (%)	EPSS (cm)
NORMAL PARAMETER	4.5-5.5	<2.7	1.3	<1.6	28-40	40-100	<0.6
PATIENT	NA	NA	NM	1.5	32	61	NM
CANINE CARDIAC PARAMETERS	HR (BPM)	AV VMAX (m/s)	PV MAX (m/s)	BODY WEIGHT (kg)	LA 2D short axis Base view (cm)	LVIDd Avg; 2D and m-mode short axis (cm)	LVIDs Avg; 2D and m-mode short axis (cm)
NORMAL PARAMETER	50-100	0.7-1.7	0.7-1.6	BELOW	BELOW	BELOW	BELOW
PATIENT	150	2.5	1.5	22.3	2.5	3.5	2.4
*Normal chamber parameters expressed as a mean value (SD)				3	1.27 (5.3)	2.46 (2.46)	1.36 (5.5)
BODY WEIGHT DEPENDENT PARAMETERS				5	1.40 (4.5)	2.74 (5.2)	1.60 (4.7)
<i>*Note: All measurements based upon multi-modal images and methods. An average value is reported.</i>				10	1.50 (3.8)	3.27 (3.5)	2.06 (3.1)
				15	1.83 (2.0)	3.71 (2.4)	2.43 (2.1)
				20	2.02 (1.9)	4.14 (2.2)	2.80 (2.0)
				25	2.18 (2.4)	4.48 (2.9)	3.10 (2.5)
				30	2.33 (3.3)	4.83 (3.9)	3.39 (3.4)
				35	2.48 (4.3)	5.17 (5.0)	3.69 (4.5)
				40	2.62 (5.2)	5.48 (6.1)	3.96 (5.4)
				50	2.88 (7.1)	6.07 (8.3)	4.46 (7.4)

INTERPRETATION OF THE FINDINGS & FURTHER RECOMMENDATIONS

Compared to the prior study, findings are similar. The aortic outflow velocity is mildly elevated with a small insufficiency seen. No progression is seen and the LV remains normal, suggesting the disease is subclinical. No additional issues have developed.

Given these findings, no cardiac medications are indicated at this time. From a cardiac standpoint, monitor for development of collapse episodes, labored breathing or exercise intolerance, as AS



PATIENT

Paisley Roshuk

patients are more predisposed to development of arrhythmias than to CHF (particularly Boxers and Bulldogs).

SPECIES

Canine

Anesthetic risk is low. Avoid heart rate stimulating drugs such as atropine or glycopyrrolate unless clinically indicated. Recommend prophylactic antibiotics for any orthopedic or dental procedure in the future given slight predisposition to endocarditis.

BREED

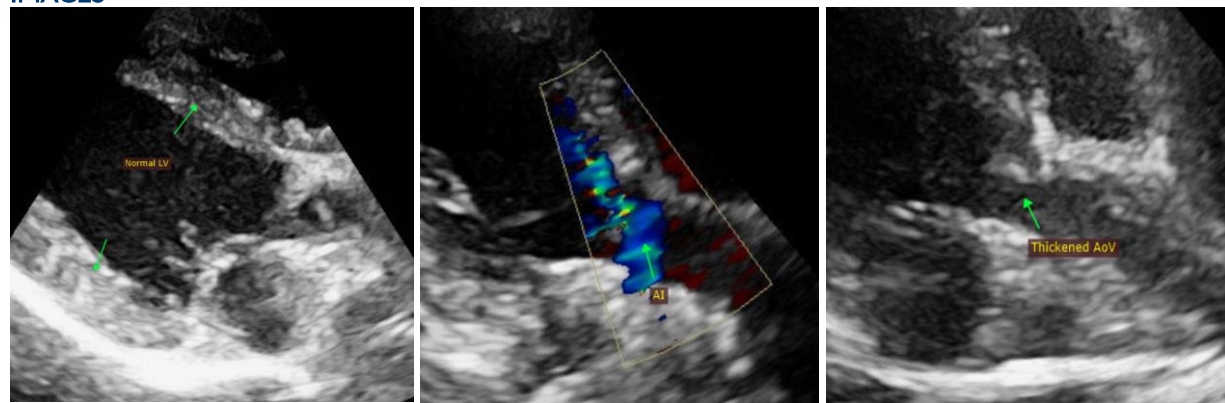
Boxer

Recommend recheck echocardiogram in 12-18 months, sooner if any clinical signs arise.

IMAGES

SEX

Female Spayed



AGE

4years

WEIGHT

49.2lbs

The information and recommendations provided are based on the images presented by the referring veterinarian. No evaluation can be communicated regarding pathology that was not visible in the image/video clips provided.

INTERPRETED BY

Maggie Machen Lamy,
DVM, DACVIM
(Cardiology)

Thank you for this referral. This report was generated using transcription software, and minor dictation errors may be present. If the clinical or image interpretation does not parallel your findings or if I can be of any further assistance, please contact me.

IMAGING PERFORMED BY

C. Belan, DVM

Maggie Machen Lamy, DVM
Diplomate of the American College of Veterinary Internal Medicine (Cardiology)
info@sonopath.com

HOSPITAL NAME

Fish Creek Animal
Clinic

REFERRING VET

Dr. Van Sluys

INVOICE

29639

DATE

3/16/23